

Dental Review™

Making Education Easy

Issue 41 – 2014

In this issue:

- > Laser pulpotomy
- > Dams and posts
- > Debonding veneers
- > Cutaneous sinuses
- > Denture stomatitis
- > Calcium hydroxide removal
- > Sedation, anxiety and pain
- > Periapical and heart diseases
- > LA for painful molars
- > Quantic molecular resonance scalpel



New Zealand Dental Therapists' Association
(Incorporated)

Dental Review is also made available to Dental Therapists through the kind support of the New Zealand Dental Therapists' Association

Welcome to Issue 41 of Dental Review. Some newish devices here, from lasers to quantic resonance scalpels and irrigation aids. Also a return to an old favourite; another investigation of the potential benefits of the dental (rubber) dam, which was 150 years old last year. How did I miss that opportunity for a party?

Best wishes,

Nick Chandler

Associate Professor

Department of Oral Rehabilitation, University of Otago

nickchandler@researchreview.co.nz

Laser-assisted pulpotomy in primary teeth: a systematic review

Authors: De Coster P et al.

Summary: Pulpotomy aims to remove the infected/inflamed coronal pulp while preserving the healthy radicular tissue beneath. Lasers might offer good haemorrhage control while stimulating regenerative cells. This review identified articles comparing lasers to conventional pulpotomy techniques. Seven articles met the inclusion criteria, and 4 different types of lasers were used in the studies. A variety of materials were placed on the pulp stumps, including MTA, GIC, IRM and other zinc eugenols. The statistics indicated that laser use was less successful than conventional methods.

Comment: A similar result here to research findings from studies of the permanent dentition. Conclusions are complicated by the different laser types, the variety of frequencies used and ages of the patients. How much of the pulp response is the effect of the irradiation, and how much is due to the material? Maybe MTA is all we need? Meta-analyses suggest that MTA and ferric sulphate could be replacements for formocresol, considered for many years to be the 'gold standard' for primary teeth.

Reference: *International Journal of Paediatric Dentistry* 2013;23:389-399

[Abstract](#)

Dental Review

Independent commentary by Associate Professor

Nick Chandler of the Department of Oral Rehabilitation, University of Otago.

For full bio [CLICK HERE](#)



NEXT
GENERATION

A strong
bond,
proven performance.

Multilink Automix

Multilink® Automix

The adhesive cementation system

Now with advanced formula

Strong hold – both dual and self-curing

Universal – suitable for silicate and oxide ceramics as well as metal

Clinically proven – numerous long-term studies

New – additional shade, improved handling

Recommended for
US e.max™

ivoclar
vivadent
passion vision innovation

Freephone: 0508 IVOCLAR (486 252) | Email: info.nz@ivoclarvivadent.com

Rubber dam use during post placement influences the success of root canal-treated teeth

Authors: Goldfein J et al.

Summary: These investigators reviewed the notes of 185 patients with an average recall of 2.7 years, looking for new periapical lesions after root treatment and placement of a prefabricated post. Two groups were studied based on the presence of a dam clamp in a radiograph taken during post placement. Thirty teeth had posts with a dam in use and 174 without. In the dam group 93% of teeth were successful, compared to 74% without a dam. This was statistically significant.

Comment: The recommended time to prepare a post space for an indirect post or to cement a preformed post is during the root filling appointment when a dam is on and when one is familiar with the orientation and length of the root canal. I'm sure many dentists treat anterior (and perhaps some posterior) teeth under a dam without using a clamp, preferring to use Wedgets, strips of dam material, floss ligatures and other retentive devices. This may have biased the data? The authors 'warn against drawing too many unwarranted conclusions' from the study and recommend more research. Probably a worthwhile caution.

Reference: *Journal of Endodontics* 2013;39:1481-1484

[Abstract](#)

[CLICK HERE](#)

to read previous issues of
Dental Research Review

Oral Sleep Medicine
7th Annual Course

IN THE JAWS OF TIME

Perth Convention & Exhibition Centre
7-8 October 2014

 Offered by the
Australasian Sleep Association

www.sleep.org.au

Effect of Er:YAG laser on debonding strength of laminate veneers

Authors: Iseri U et al.

Summary: The authors used bovine teeth and cylindrical specimens (0.7 mm x 5 mm) of Empress II to mimic veneers. These were attached with a dual-cured cement and one group was 'scanned' for 9 seconds using an Er:YAG laser. The shear force to remove the veneers was then measured, with the lasing shown to have significantly decreased the bond strength.

Comment: An easy way to remove veneers (and hopefully of retrieving them intact and not damaging the tooth beneath) would be useful. Resin cements contain water or residual monomer which absorbs laser light. Unfortunately, this interesting research did not look at potential damage to the underlying tooth, and one can assume that other ceramic materials and cements will behave differently.

Reference: *European Journal of Dentistry* 2014;8(1):58-62

[Abstract](#)

Facial cutaneous sinuses of dental origin – a diagnostic challenge

Authors: Sammut S et al.

Summary: While some chronic periapical lesions drain to the mouth, a few present on the skin through a sinus tract. This article features 5 case reports and reviews the literature. There are 4 times as many of these lesions from mandibular teeth than maxillary teeth. Half come from mandibular incisors or canines, so are seen on the chin or submental region. Inserting a gutta percha point and taking a radiograph may help to locate the source.

Comment: These are rarely seen, and when they turn up the camera comes out. Examples in my collection look just like Figure 2 from this paper. Patients had also attended after months or years of ineffective treatment and were amazed to be cured by attention inside the mouth. The tracts often close within a week of commencing treatment. Sadly, one of the references in the paper is dated 1997 and describes a patient having radiotherapy.

Reference: *British Dental Journal* 2013;215:555-558

[Abstract](#)

Privacy Policy: Research Review will record your email details on a secure database and will not release them to anyone without your prior approval. Research Review and you have the right to inspect, update or delete your details at any time.

Disclaimer: This publication is not intended as a replacement for regular medical education but to assist in the process. The reviews are a summarised interpretation of the published study and reflect the opinion of the writer rather than those of the research group or scientific journal. It is suggested readers review the full trial data before forming a final conclusion on its merits.

Research Review publications are intended for New Zealand health professionals.

**Find healthcare jobs
in your area**

**trade me
JOBS** 
www.trademe.co.nz/jobs

Linking evidence to treatment for denture stomatitis: a meta-analysis of randomized controlled trials

Authors: Emami E et al.

Summary: How does antifungal therapy compare with other ways of treating denture stomatitis? The investigators examined randomised controlled trials reported in English or French, recording signs of denture stomatitis and reduction in *Candida* in the literature. From 233 articles, 15 reporting 14 trials were selected for review and 8 for meta-analysis. No significant difference was found between antifungals and disinfection methods for both clinical and microbiological outcome. The meta-analysis favoured antifungals for microbiological outcome but showed no difference between antifungal and placebo for clinical outcome.

Comment: A complicated but interesting study; the authors state that no cause and effect relationship has been shown between *Candida* and denture stomatitis. There is a useful list here of disinfection agents and other methods that have antimicrobial and antifungal action, which can explain positive outcomes.

Reference: *Journal of Dentistry* 2014;42:99-106
[Abstract](#)

Evaluation of calcium hydroxide removal using EndoActivator system: an *in vitro* study

Authors: Al-Garni S et al.

Summary: The EndoActivator is a battery-powered handpiece that 'whips' a disposable flexible polymer tip inside root canals to agitate irrigants. In this experiment, 44 single-rooted mandibular premolars had canals prepared and Calasept calcium hydroxide dressings were placed. After one week, a K-file was used to loosen the material and the canals irrigated. In one group of teeth the irrigant was agitated for one minute. Teeth were then split and examined using a scanning electron microscope. Ca(OH)₂ particles were completely removed in the coronal parts of the canals in all cases. The activator device did not improve cleaning in the apical and middle thirds.

Comment: It is amazing how difficult it is to completely remove calcium hydroxide dressings. The material used here was saline-based but some are viscous and more complicated to remove. The EndoActivator is an easy to use and relatively inexpensive device, and seems efficient at dressing removal in immature teeth with very wide root canals. I don't think these have been subjected to a laboratory study yet; perhaps bovine incisors would be a realistic model for this?

Reference: *Saudi Endodontic Journal* 2014;4:13-17
[Abstract](#)

Effects of conscious sedation on patient recall of anxiety and pain after oral surgery

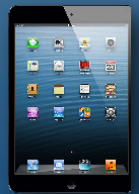Authors: Wilson TD et al.

Summary: Patients having a surgical extraction with local anaesthetic (LA) alone were compared with a similar group of 27 people who also received moderate sedation with midazolam. Both groups reported their fear, anxiety and pain initially and one month after the procedure when they mailed back a survey form. The midazolam patients recalled less procedural pain and anxiety after one month. The LA-alone group reported more pre-extraction pain and anticipated more anxiety.

Comment: After I had sedation I walked from the operating table to a hospital bed and can't remember a thing; I shudder to think what I might have said to the nurses! The study here had somewhat different groups. Those having just the LA were 'emergencies' seeking relief of pain, while the sedated group had a planned and scheduled procedure. Also, the dose of midazolam given for moderate sedation is not exact. Nonetheless, knowing that you will receive moderate sedation gives rise to expectations of less anxiety during the procedure.

Reference: *Oral Surgery, Oral Medicine, Oral Pathology* 2014;117:277-282
[Abstract](#)

Congratulations to Lye Funn Ng, a pharmacist who has returned to Otago University to study full-time. Lye Funn is the winner of an iPad Mini from our recent Subscriptions Update competition.



Funding ?
Approval ?
Access ?



how medicines are made available for Kiwis


BOOK EARLY
SAVE
20%*
* Conditions apply



RESEARCH REVIEW
is proud to be a new Accor Hotels affiliate partner

CLICK ON THE ADVERT FOR MASSIVE DISCOUNTS

on bookings in New Zealand & Fiji



Association between chronic apical periodontitis and coronary artery disease

Authors: Costa THR et al.

Summary: This cross-sectional study involved 103 patients having a coronary angiograph who had full-mouth periapical radiographs taken (14 images). The prevalence of chronic periapical periodontitis was over 41% and of coronary artery disease 65%. Patients with periapical disease had a 2.79 times higher risk of developing heart disease. The mean age of the patients was 62 years.

Comment: This study reports a very high prevalence of periapical disease, with 31% of the subjects reported as literate. Evidence suggests a link between periodontal infection and heart disease. Periapical disease is another chronic infection with many microbiological similarities, so systemic effects might be the same. These results are similar to those of a 2006 endodontic study, but there remains a lack of research on this topic.

Reference: Journal of Endodontics 2014;40:164-167

Abstract

Efficacy of single buccal infiltrations for maxillary first molars in patients with irreversible pulpitis: a randomized controlled clinical trial

Authors: Atasoy Ulusoy ÖI, Alaçam T

Summary: The authors evaluated two 4% articaine solutions, one with epinephrine and the other with epinephrine bitartrate, used to obtain adequate pulpal anaesthesia in the palatal roots of maxillary first molars with irreversible pulpitis. The expectation was that the bitartrate formulation would be more effective due to its water-soluble nature. Ten minutes after infiltration, access was made and then files positioned in the mesiobuccal, distobuccal and palatal canals. Discomfort was rated during the process, heart rates recorded and the pulpectomy stopped if the patient felt any pain. There were higher pain scores and elevated heart rates when negotiating the palatal canals, and no significant difference was found between the two solutions.

Comment: Reliable and effective anaesthesia in emergencies for teeth with 'hot' pulps is not always achieved. I found this a rather disappointing study. The sequence of file placement in the canals should have been randomised. I wrongly assumed the experiment might have also involved a group of patients having a palatal infiltration too, as I wondered if this would help.

Reference: International Endodontic Journal 2014;47:222-227

Abstract

COMING SOON

Sleep Medicine Research Review™

CLICK HERE TO SUBSCRIBE

Subscribe at no cost to any Research Review

NZ health professionals can subscribe to or download previous editions of Research Review publications at

WWW.RESEARCHREVIEW.CO.NZ

Quantic molecular resonance scalpel vs traditional scalpel in the treatment of labial mucocele: a two-center randomized controlled trial

Authors: Broccoletti R et al.

Summary: This study investigated postoperative pain, lip paraesthesia and lesion recurrence in 85 patients with labial mucoceles. A number 15 blade was compared with the new scalpel, and follow-ups were at 1 week, 1 month and 3 months. The lesions varied in size from 2 to 30 mm and the results were comparable.

Comment: A new toy, just what dentists like. I was amused to read in the Introduction that the new technique 'is based on a theory of physics' and was pleased to be enlightened further in the Discussion. It uses a flux of quanta to break molecular bonds by resonance, cutting and coagulating simultaneously without burning and with no pressure applied. I would have liked to know how many times sutures were required when the new scalpel was used. Important from a histopathological viewpoint is that specimens removed with the new scalpel featured minimal damage (20 µm) at the periphery.

Reference: Quintessence International 2014;45:331-338

Abstract

Oral Health Research Review

Another useful summary from Research Review takes a closer look at general oral health. This quarterly publication is ideal for those working as hygienists or dental therapists or for anyone with a keen interest in evidence-based oral health management. Expert commentary supplied by Dr Jonathan Leichter, DMD, Cert Perio (Harvard), University of Otago.

CLICK HERE TO SUBSCRIBE

Oral Health Research Review

Issue 14 - 2012

Making Education Easy

In this issue:

- Ocular hazards of LCBs
- Sex differences in pain
- Dental erosion in the 21st century
- Child dental neglect in the UK
- Oral health inequalities in Australian children
- Avoidance/delaying dental visits in Australia
- Identifying physical child abuse in Brazil
- Delayed factor eruption associated with supernumerary teeth
- Dental fear transference from parents to children
- Impacted canines

Welcome to Issue 14 of Oral Health Research Review.

A childhood dental neglect in the UK has been shown to be the most common dental neglect in the world. It is a dental condition that is often overlooked and is associated with a range of oral health problems. It is a dental condition that is often overlooked and is associated with a range of oral health problems. It is a dental condition that is often overlooked and is associated with a range of oral health problems.

Evaluation of ocular hazards from 4 types of curing lights

Abstract: These researchers reported ocular hazards from 4 types of curing lights (CLs) in a study conducted in a dental practice. The study was conducted in a dental practice. The study was conducted in a dental practice. The study was conducted in a dental practice.

Comment (DR): Light curing machines have become more refined and the light they produce more intense, an indication that is a cause for concern. The study conducted in a dental practice. The study was conducted in a dental practice. The study was conducted in a dental practice.